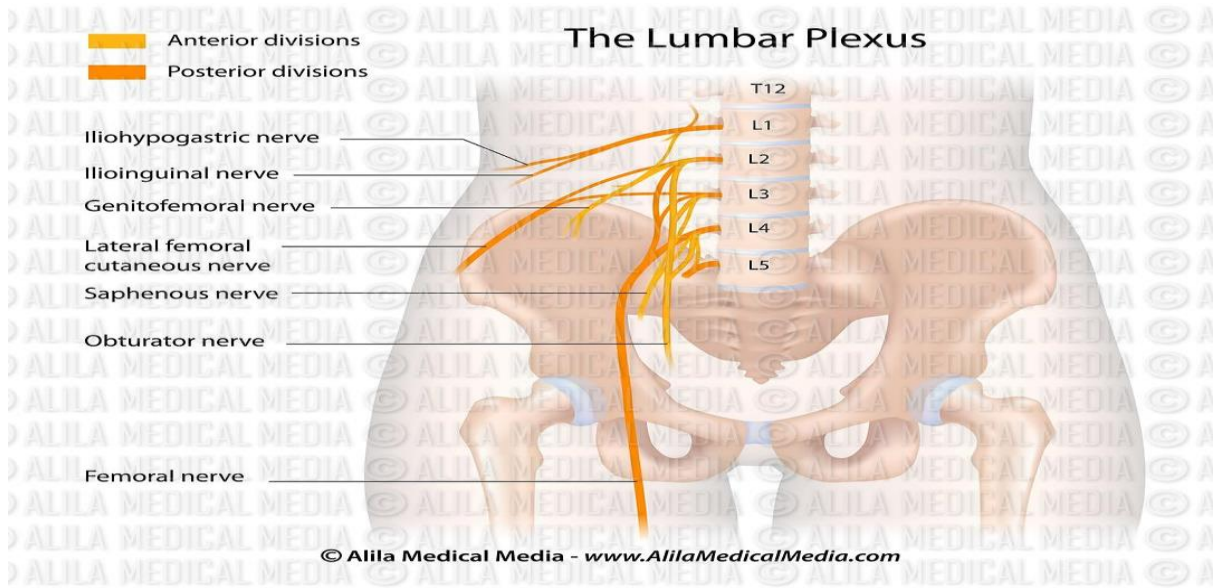
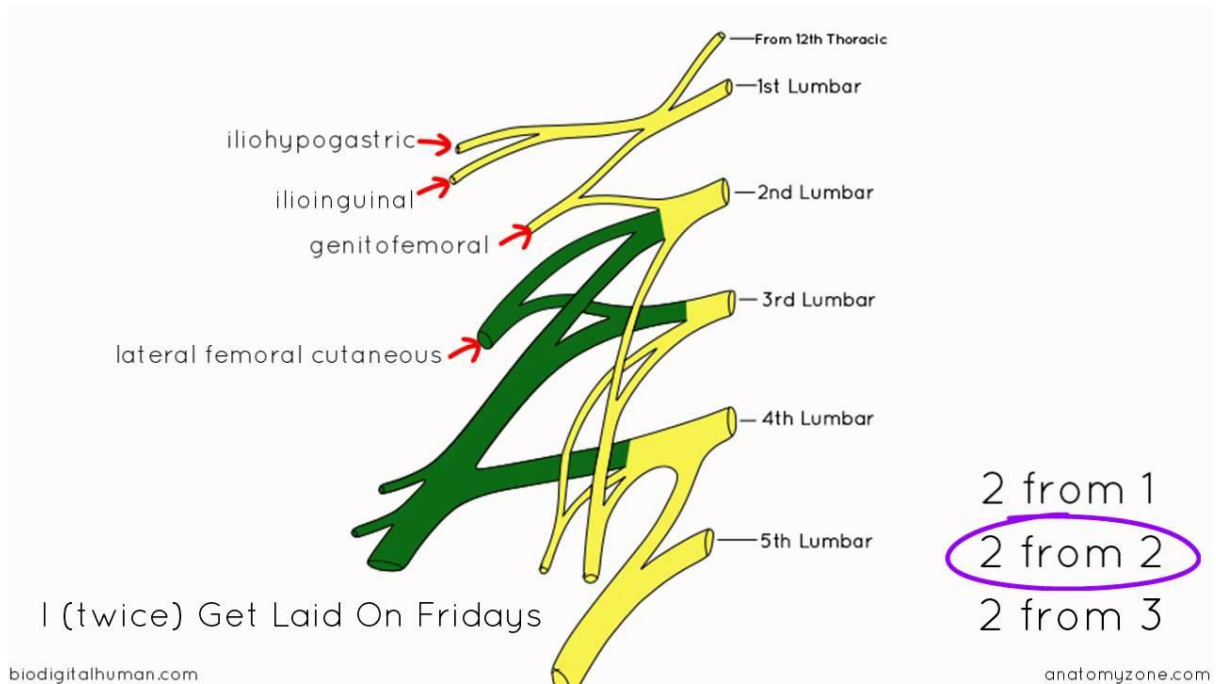


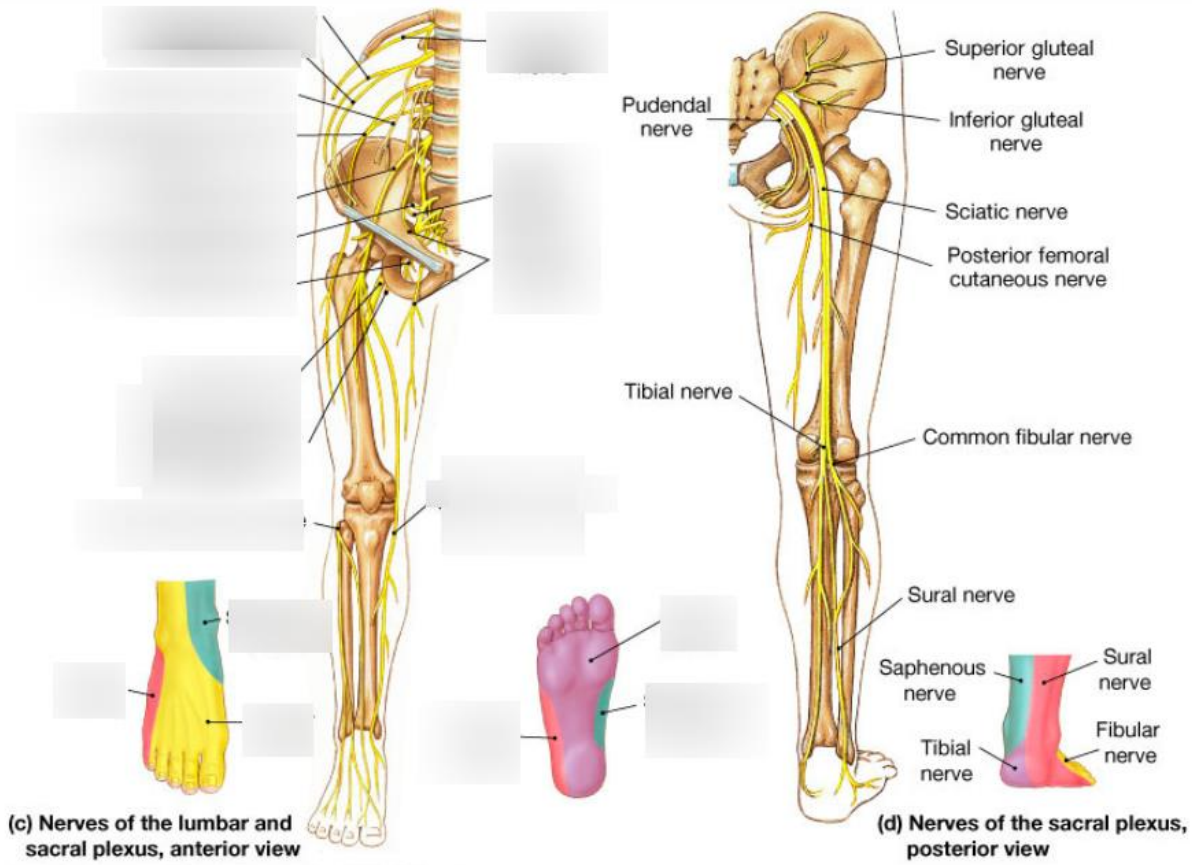
**Topic: Lower Limb – Nerve Plexuses (Lumbar & Sacral Plexuses):**



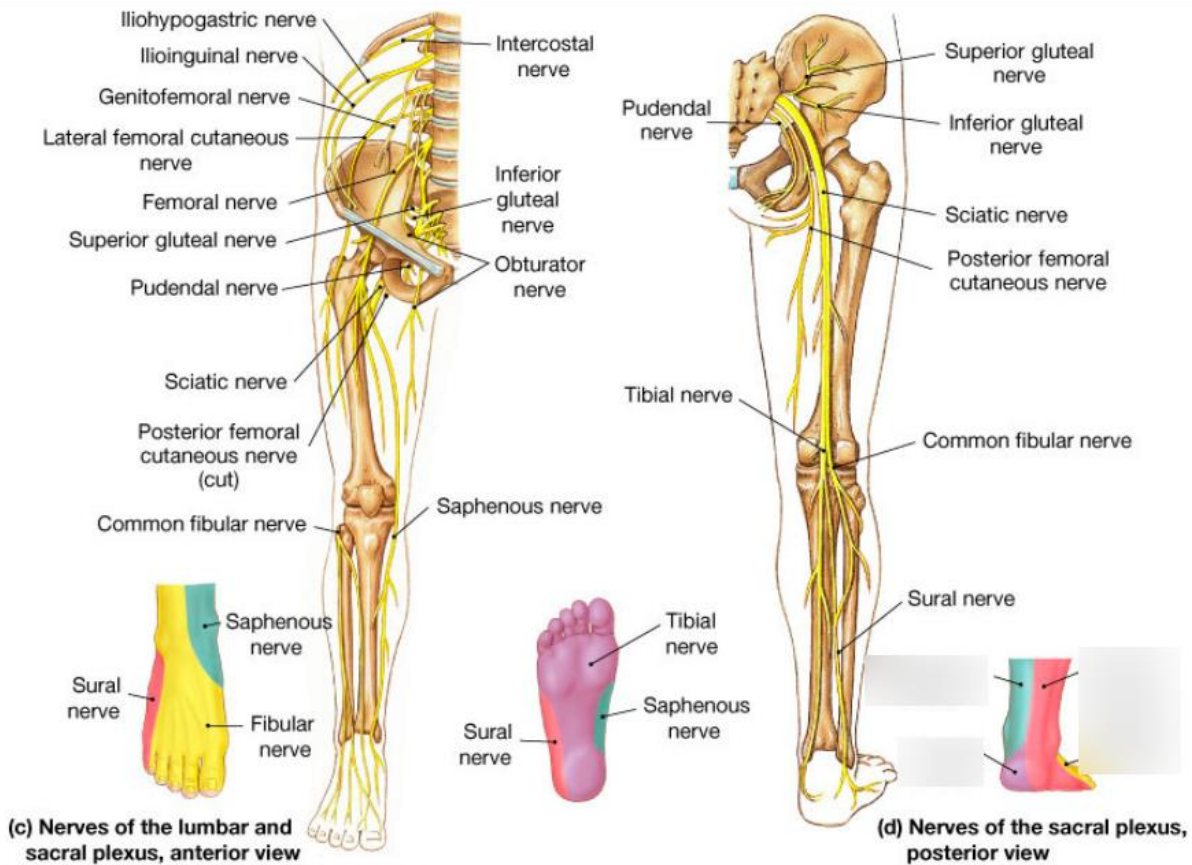
[alilamedicalmedia.com](http://alilamedicalmedia.com)



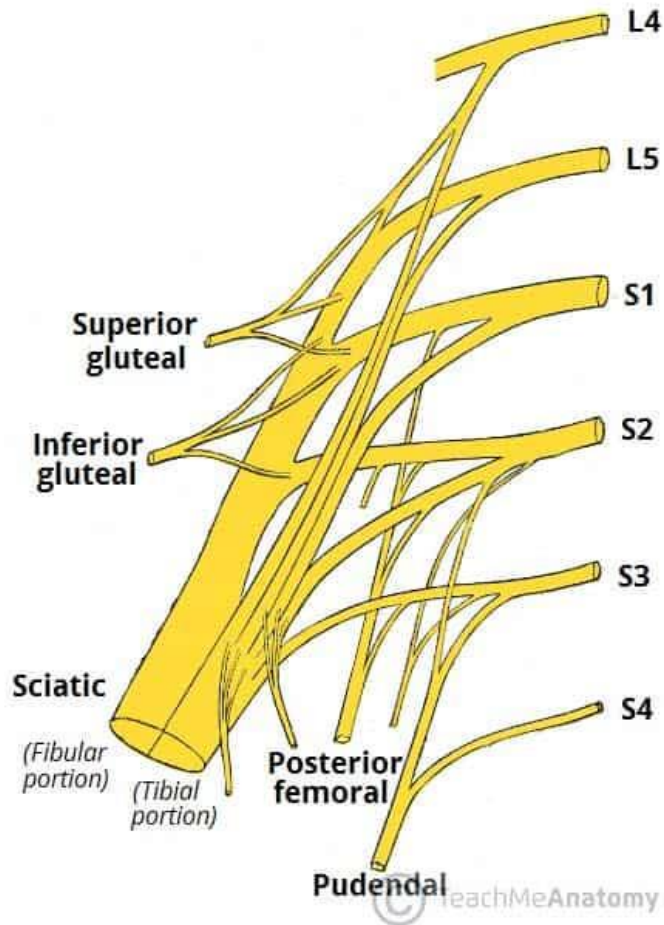
[youtube.com](https://www.youtube.com)



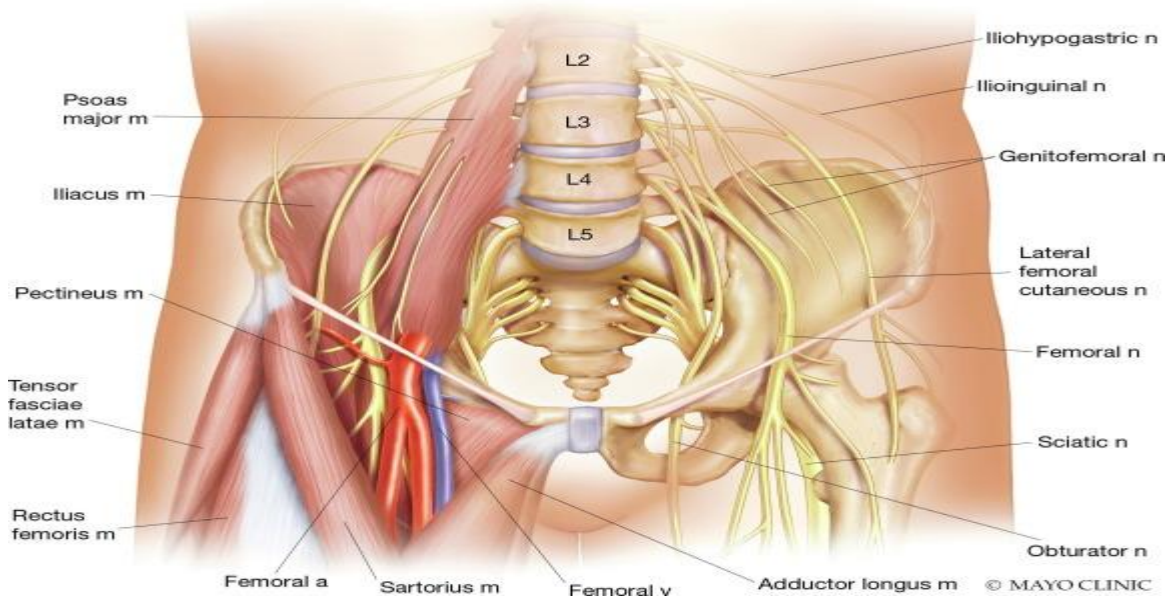
[quizlet.com](http://quizlet.com)



[quizlet.com](http://quizlet.com)



[teachmeanatomy.info](http://teachmeanatomy.info)



[sciencedirect.com](http://sciencedirect.com)

1. In the dissection hall, you trace the anterior rami supplying the lower limb. Name the TWO main plexuses formed and their primary ventral rami contributions.
2. The lumbar plexus is located where in relation to the psoas major muscle? (one phrase)
3. Identify the ventral rami forming the lumbar plexus (exact roots) and the small branch from L1-L2 that joins the sacral plexus.
4. From the lumbar plexus, name the largest branch and its root value (e.g., L2-L4).
5. The femoral nerve arises from which roots, and what is its main motor supply in the anterior thigh?
6. Identify the branch of lumbar plexus that supplies skin over the lateral thigh – name it and roots.
7. Obturator nerve: Roots? And which compartment of thigh does it primarily supply motor branches to?
8. The lumbosacral trunk is formed by which rami and connects which two plexuses?
9. Sacral plexus: Main ventral rami contributions? And where is it located (in front of which muscle)?
10. Identify the largest nerve in the body emerging from sacral plexus – name it, roots, and its two terminal divisions.
11. Sciatic nerve splits into which two branches at the popliteal fossa, and which one is larger/more lateral?
12. Pudendal nerve: Roots? And its main clinical importance (e.g., pudendal block).
13. Superior gluteal nerve (L4-S1): Exits pelvis where, and supplies which muscles (name three)?
14. Inferior gluteal nerve: Roots? And main muscle it supplies (chief extensor of hip).
15. Clinical integration: Foot drop indicates lesion of which nerve from lumbar plexus? While weak hip abduction suggests damage to which sacral plexus branch?

**ANSWER KEY:**

1. Lumbar plexus (L1-L4) and Sacral plexus (L4-S3).
2. Within the substance of psoas major.
3. L1 to L4; Lumbosacral trunk (L4-L5 part).
4. Femoral nerve (L2-L4).
5. Posterior division of L2-L4; Quadriceps femoris (knee extension).
6. Lateral femoral cutaneous nerve (L2-L3).
7. L2-L4; Adductor compartment (adductors).
8. L4 and L5 (part); Connects lumbar to sacral plexus.
9. L4-S3; In front of piriformis muscle.
10. Sciatic nerve (L4-S3); Tibial and common peroneal (fibular).
11. Tibial and common fibular (peroneal); Common fibular is lateral.
12. S2-S4; Supplies perineum (sensory/motor for childbirth anaesthesia).
13. Above piriformis; Gluteus medius, minimus, tensor fasciae latae.
14. L5-S2; Gluteus maximus.
15. Deep fibular (peroneal) branch of common fibular (from sciatic/sacral); Superior gluteal nerve