

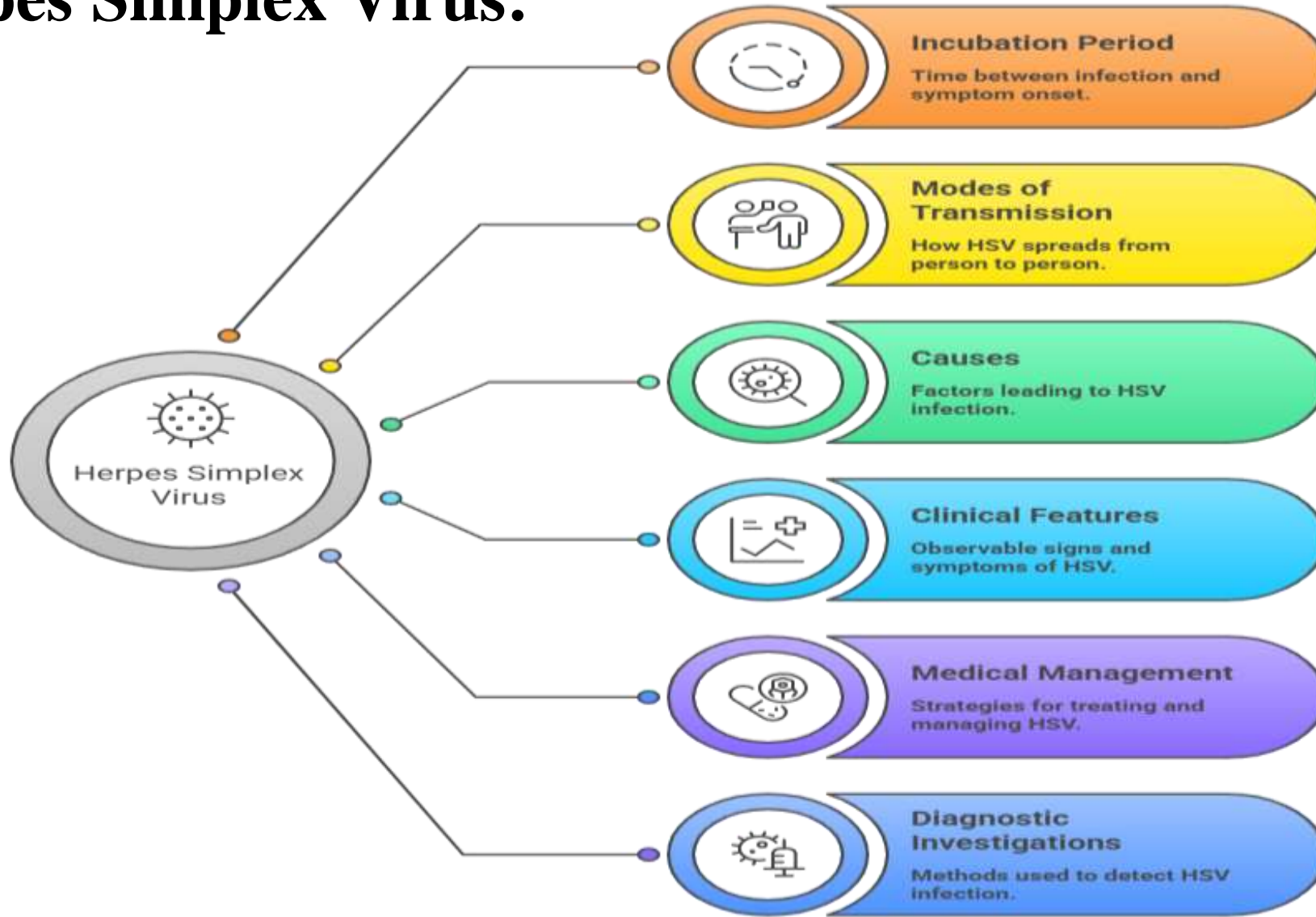
# SNS COLLEGE OF PHYSIOTHERAPY

Coimbatore -641035



**COURSE NAME** : BPT., Physiotherapy II Year  
**SUBJECT** : General Medicine/General Surgery  
**UNIT** : 1  
**TOPIC** : Herpes Simplex Virus  
**PREPARED BY** : Dr.R.Rajakrishnan MPT(NEURO)., DYHE.,  
CDNT.,CKTP., IASTM PRACTITIONER.,  
MARHYTHE PRACTITIONER.,  
Assistant professor  
SNS College of Physiotherapy

# Herpes Simplex Virus:



# Definition:

What is Herpes Simplex Virus (HSV)?

It's a double-stranded DNA virus in the \*Herpesviridae\* family.

What are the main types?

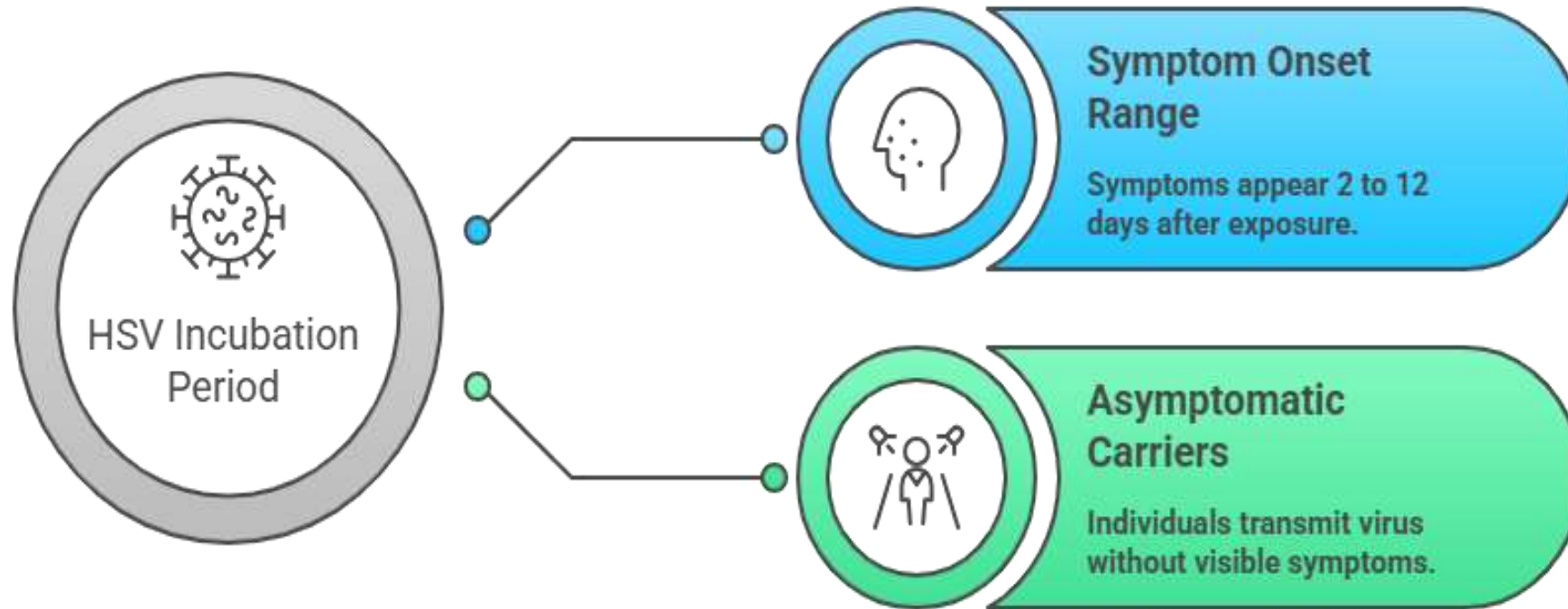
HSV-1, primarily causing oral herpes, and HSV-2, primarily causing genital herpes.

Can HSV-1 cause genital herpes and HSV-2 cause oral herpes?

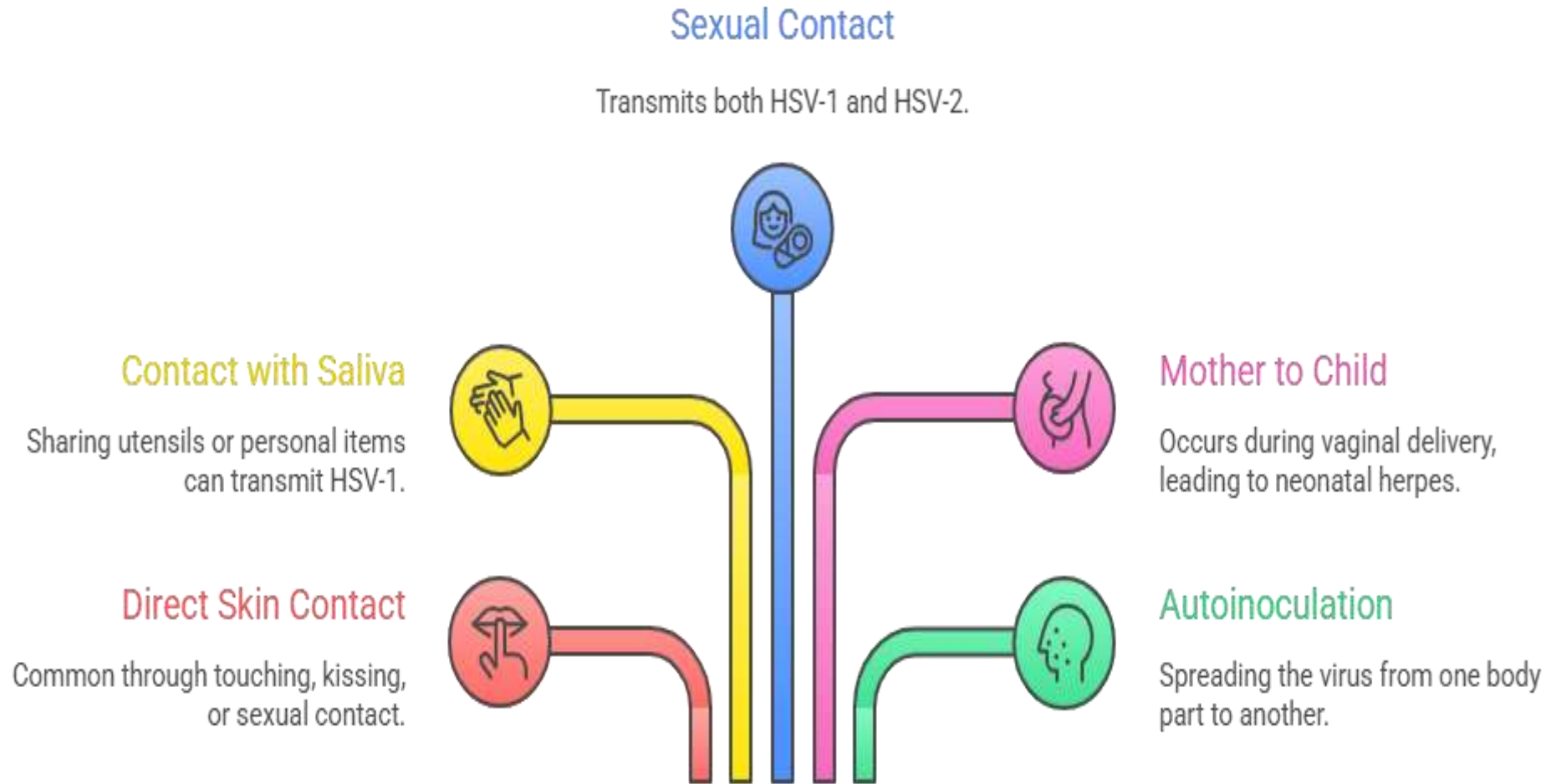
Yes, both types can cause infections in either location.



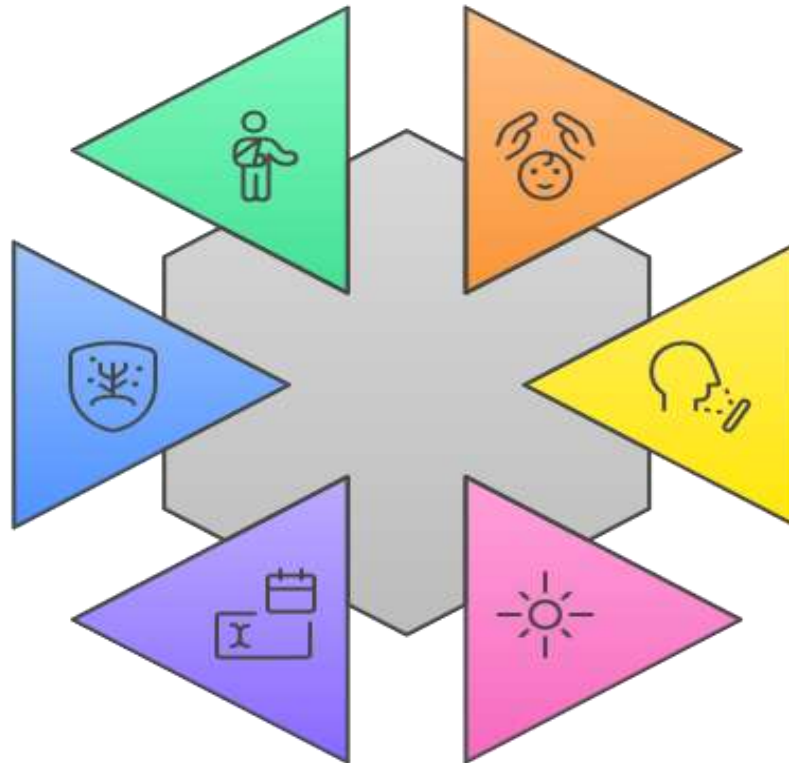
# Incubation Period:



# Mode of Transmission:

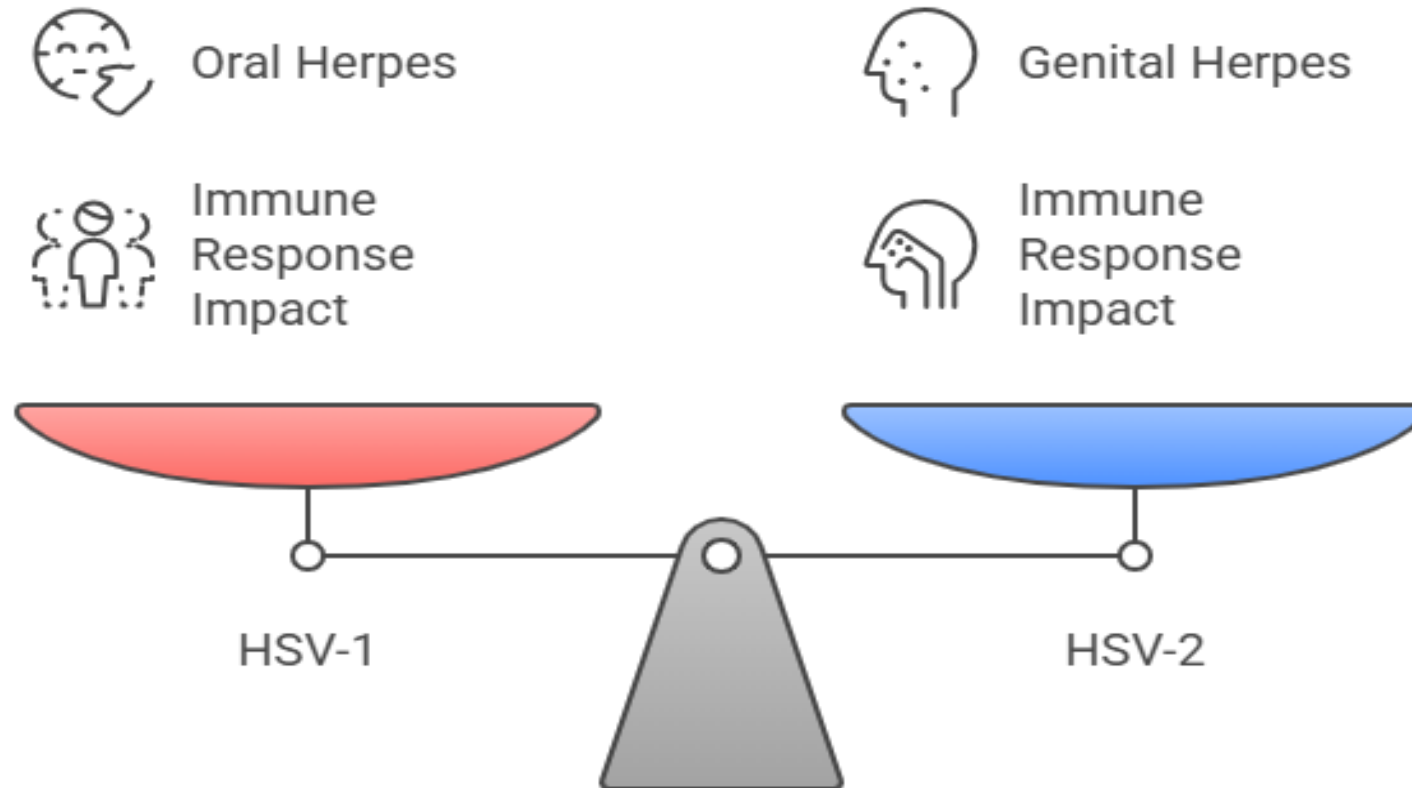


# Causes:



- Stress**  
Physical or emotional stress weakening the immune system
- Illness**  
Other infections triggering outbreaks
- Sunlight Exposure**  
Prolonged exposure triggering oral herpes
- Menstruation**  
Hormonal changes triggering genital herpes
- Weakened Immune System**  
Conditions suppressing the immune system
- Trauma**  
Local skin trauma triggering outbreaks

# Clinical Features:



# Oral Herpes (HSV-1):

## Gingivostomatitis

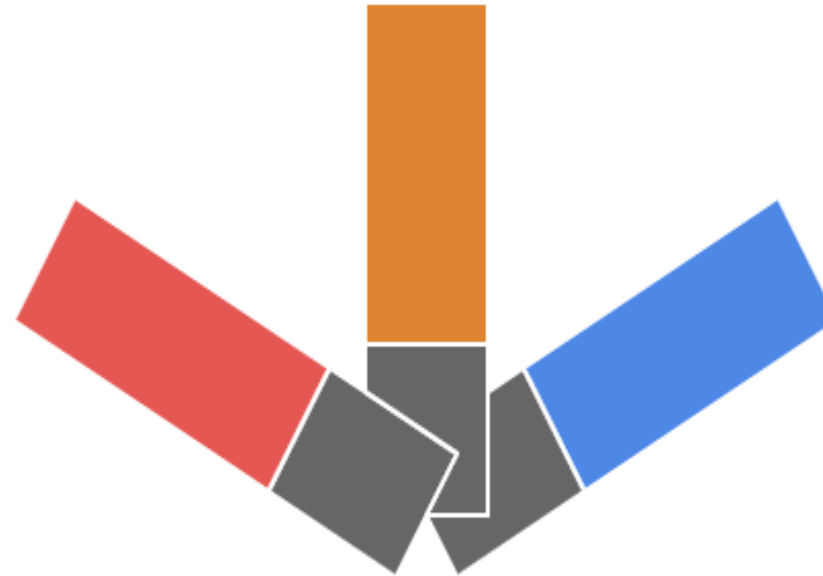
Inflammation of the gums and oral mucosa, common in children.

## Cold Sores/Fever Blisters

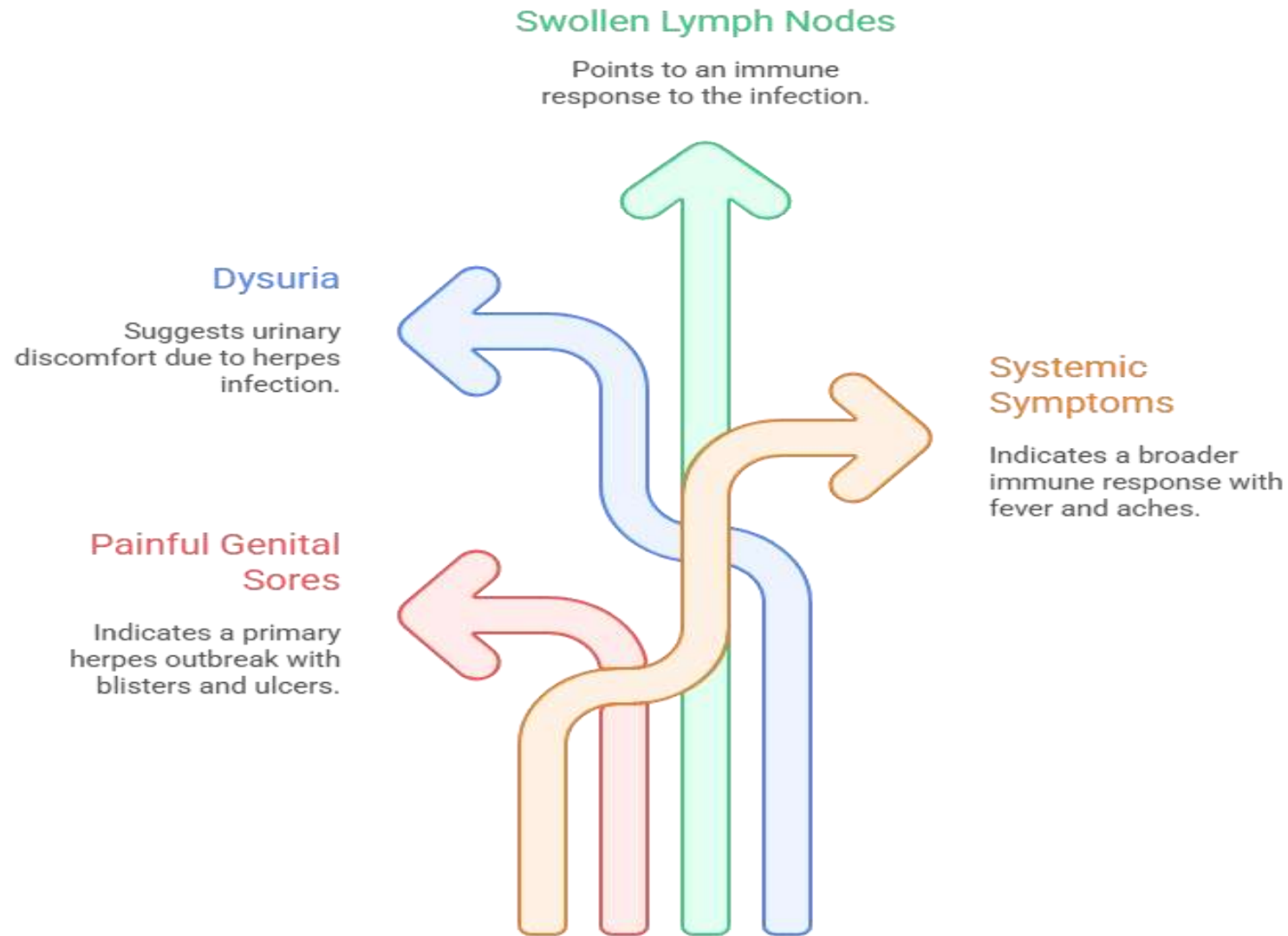
Small, painful blisters on or around the lips, often preceded by itching or burning.

## Pharyngitis

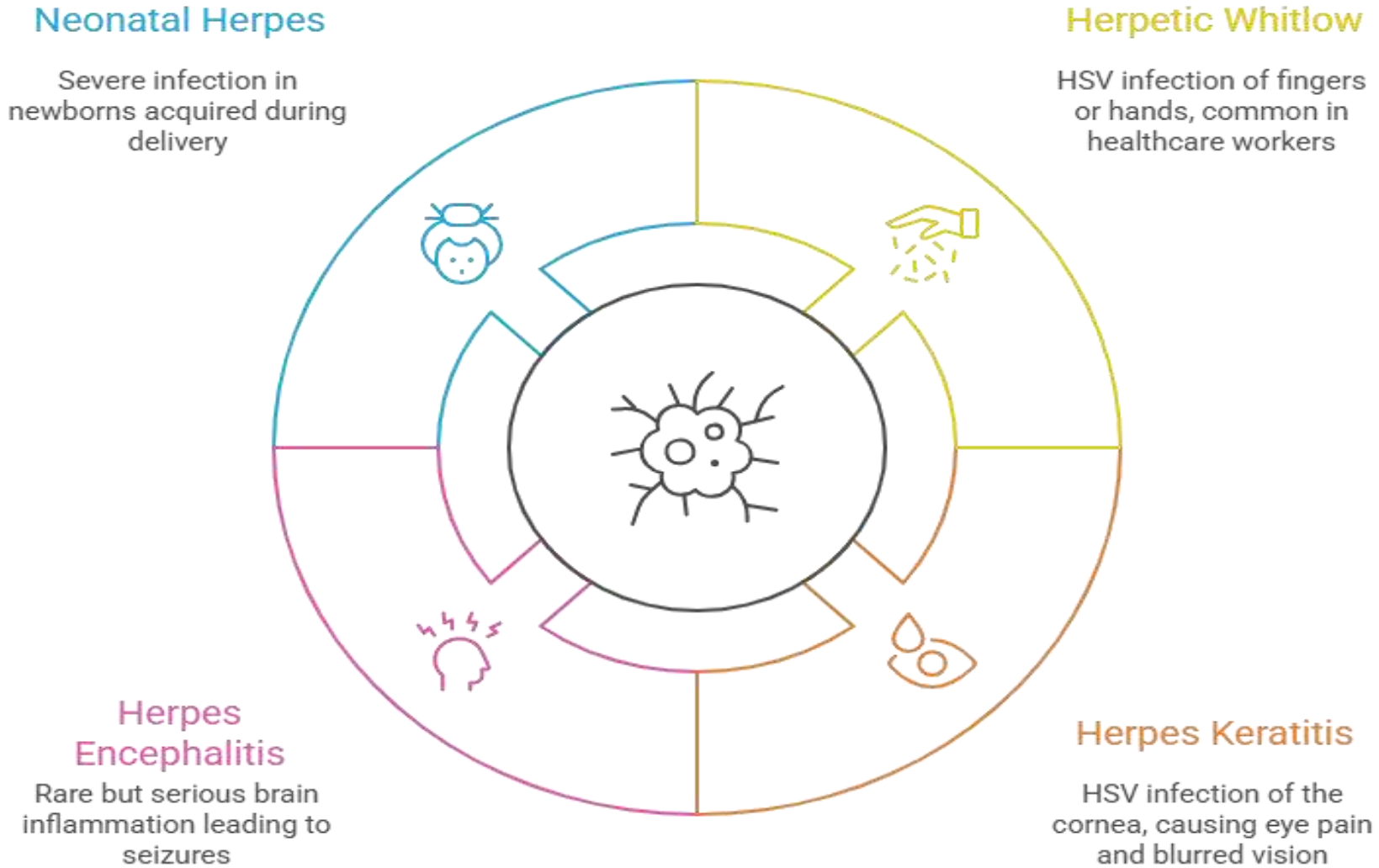
Sore throat and difficulty swallowing.



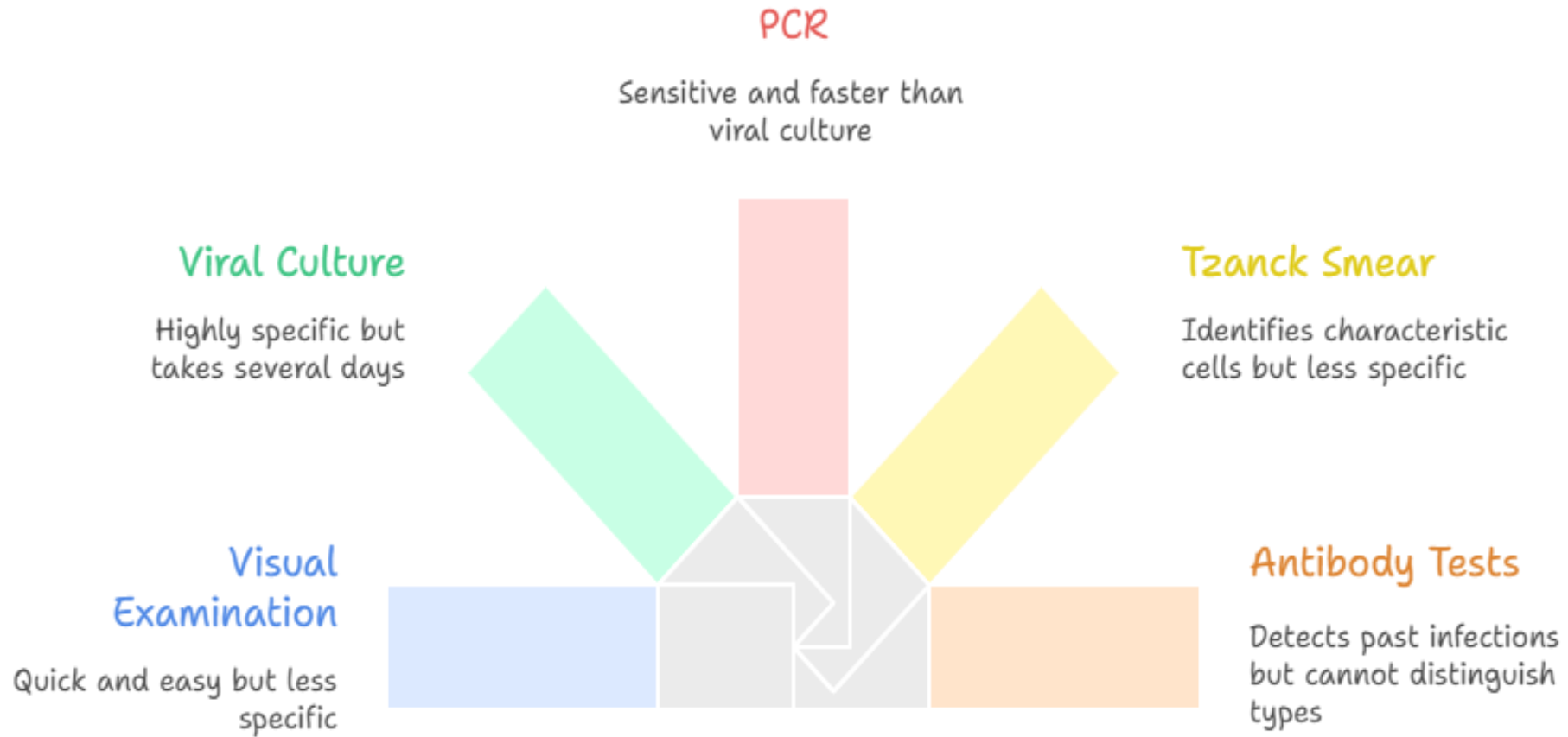
# Genital Herpes (HSV-2, but can also be HSV-1):



# Other Manifestations:



# Investigation:



# Inclass Assessment:



## Case Study (Read Before MCQs)

A **26-year-old female** presents to the outpatient department with **painful fluid-filled blisters around the lips** associated with **burning sensation and mild fever** for 2 days. She reports a history of **similar episodes in the past**, often occurring during **periods of stress and lack of sleep**.

On examination:

- Multiple **grouped vesicles on an erythematous base** around the lips
- Local tenderness present
- No lymphadenopathy
- No systemic complications

## 5. Which of the following factors is a common trigger for reactivation of HSV?

- A. Physical exercise
- B. Stress and fatigue
- C. High-protein diet
- D. Antibiotic use

## Case-Based MCQs

### 1. The most likely diagnosis in this patient is:

- A. Impetigo
- B. Aphthous ulcer
- C. Herpes Simplex Virus infection
- D. Herpes Zoster

### 2. The virus most commonly responsible for this presentation is:

- A. HSV-2
- B. Varicella-zoster virus
- C. Epstein–Barr virus
- D. HSV-1

### 3. The typical appearance of the lesion in HSV infection is best described as:

- A. Single painless ulcer
- B. Grouped vesicles on erythematous base
- C. Thick crusted lesion
- D. Diffuse maculopapular rash

### 4. The recurrence of symptoms in this patient is due to:

- A. Reinfection from environment
- B. Poor immunity
- C. Latent virus reactivation in nerve ganglia
- D. Incomplete treatment