

SNS COLLEGE OF PHYSIOTHERAPY

Affiliated To The Tamil Nadu Dr. MGR Medical University, Chennai
Coimbatore – 641035

COURSE NAME : BIOMECHANICS

SUBJECT CODE : 6277

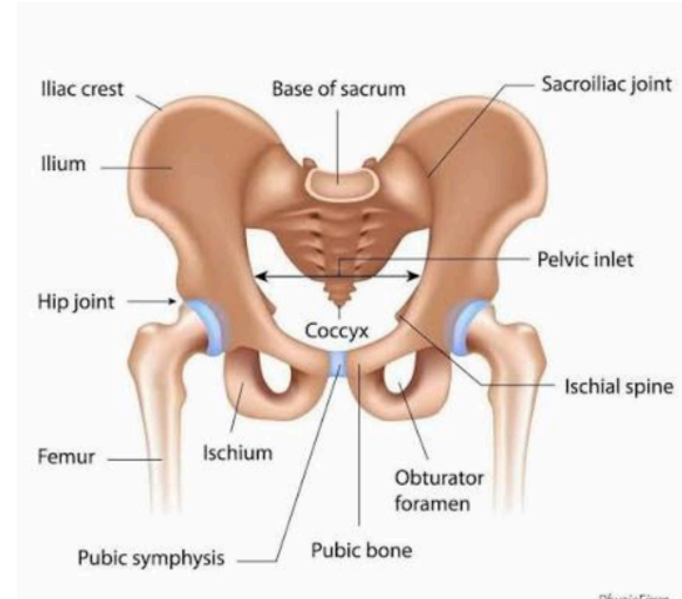
TOPIC : HIP JOINT

EMPATHIZE

Hip joint is a synovial, ball-and-socket joint

Formed by:

- **Head of femur**
- **Acetabulum of pelvis**



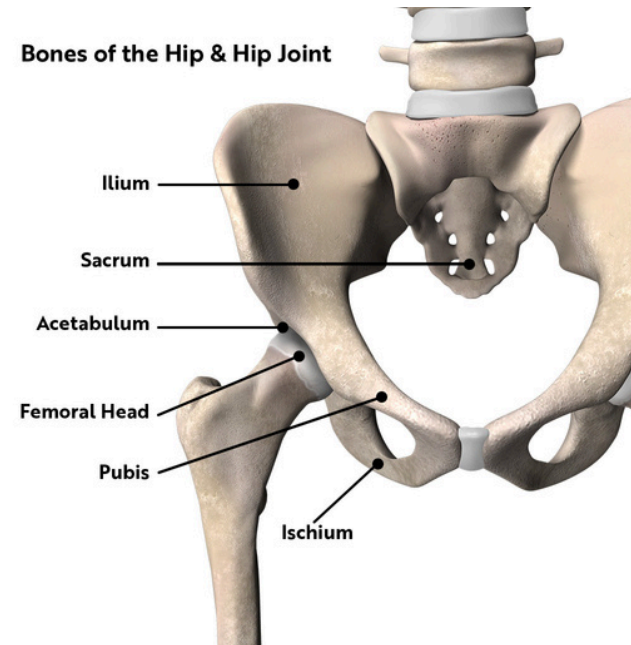
Designed for weight bearing and mobility

IDEATE

Knowledge helps in:

- **Prosthetic design**
- **Fracture management**
- **Physiotherapy planning**
- **Structural alignment improves joint**

longevity

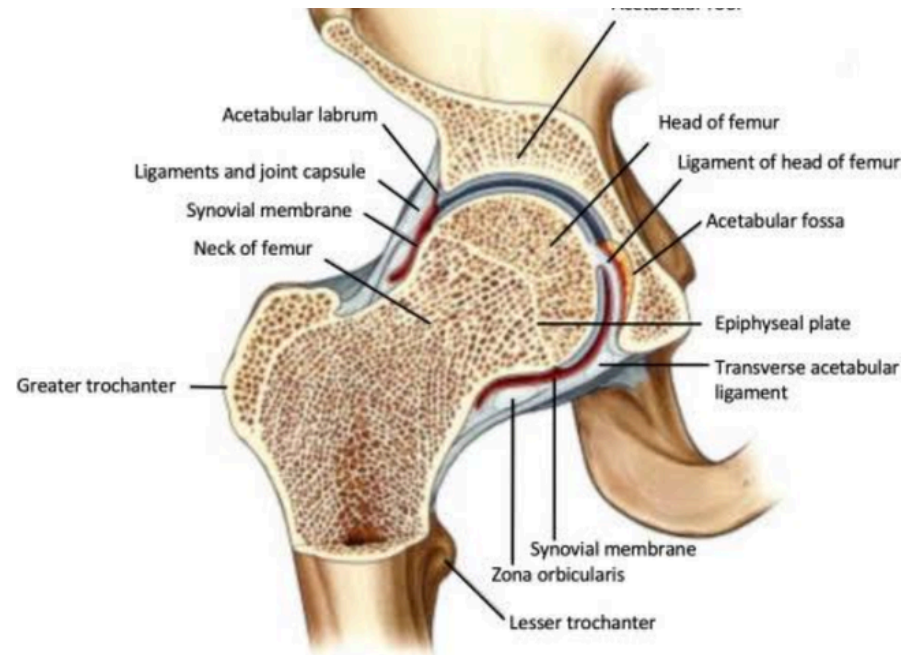


DEFINE AND EXPLAIN

Bears body weight during standing and walking
Structural defects lead to:

- **Pain**
- **Gait abnormalities**
- **Reduced independence**

Commonly affected in arthritis and fractures

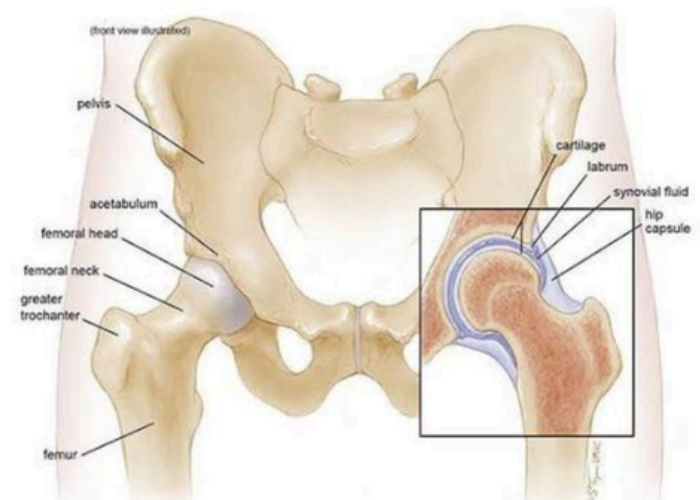


ARTICULATING SURFACES

**Pelvis: Acetabulum with
lunate surface & labrum**

**Femur: Spherical femoral
head**

**Deep socket increases
stability**



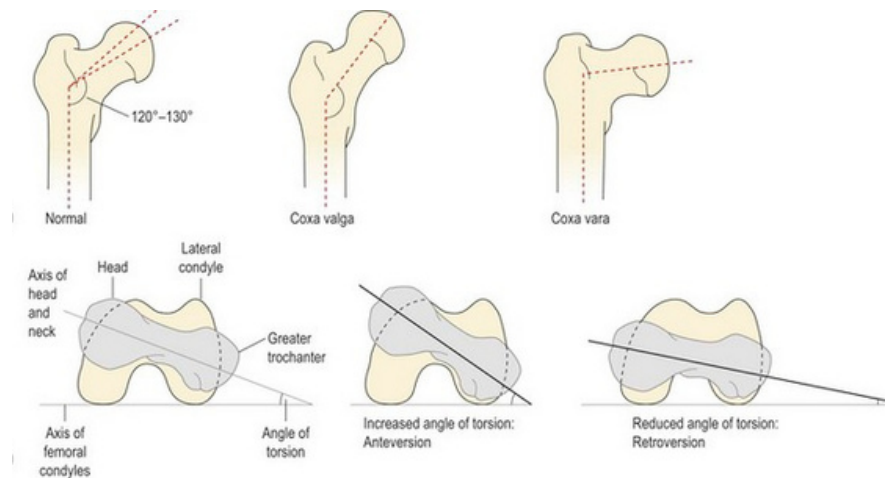
ANGULATIONS AND TORSION

Neck-shaft angle:

~125°

Angle of torsion: 10-15° anteversion

Affects load distribution and gait



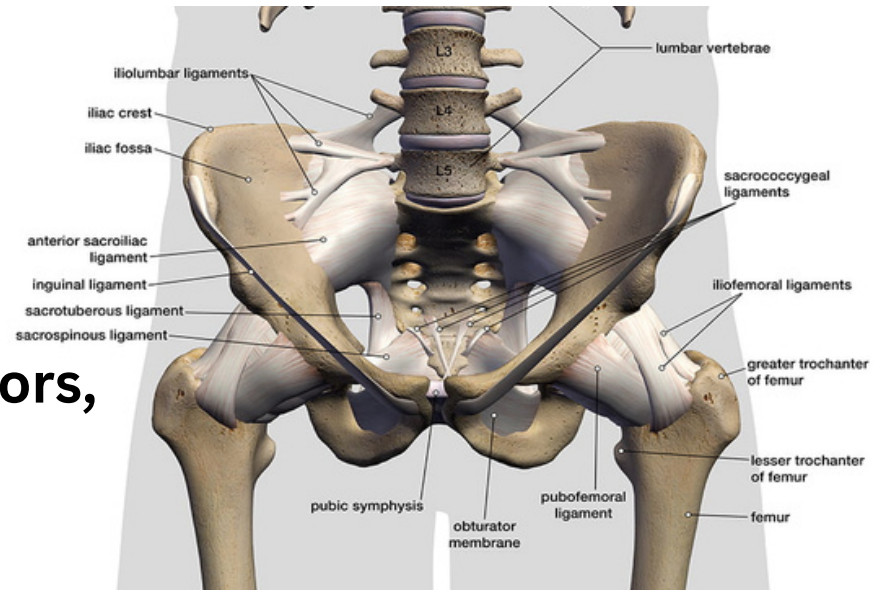
LIGAMENTS AND MUSCLES

Ligaments: Iliofemoral,

Pubofemoral, Ischiofemoral

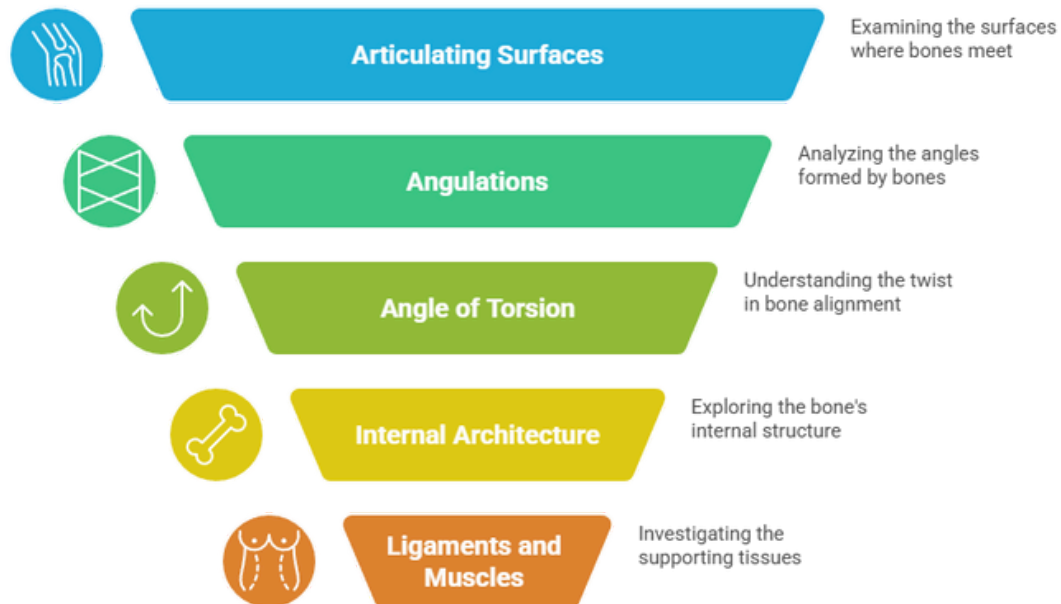
**Muscles: Flexors, extensors, abductors,
rotators**

Ligaments provide passive stability



FLOW CHART

Hip Joint Structure Analysis



Made with  Napkin

In class assessment

1. Define the hip joint and classify it structurally and functionally.

2. Describe the articulating surface on the pelvis forming the hip joint.

(Include acetabulum, lunate surface, acetabular labrum, and acetabular notch.)

3. Describe the articulating surface on the femur involved in the hip joint.

(Include head of femur, fovea capitis, and cartilage covering.)

4. Explain the normal angulations of the femur in relation to the hip joint.

(Include angle of inclination and its normal value.)

5. Define the angle of torsion (femoral anteversion). State its normal range and clinical significance.

In class assessment

5. Define the angle of torsion (femoral anteversion). State its normal range and clinical significance.

6. Describe the internal architecture of the femur related to weight transmission.

(Include trabecular patterns, principal compressive and tensile trabeculae, and Ward's triangle.)

7. Describe the internal architecture of the pelvis involved in load transmission at the hip joint.

8. Enumerate and describe the ligaments of the hip joint.

(Iliofemoral, pubofemoral, ischiofemoral ligaments, ligamentum teres, and transverse acetabular ligament.)

9. Describe the muscular support of the hip joint.

(Mention major muscle groups and their role in stability.)

10. Explain how the structural features of the hip joint provide stability while allowing mobility.

Thank you

